



**DR. LORIN BERLAND**

A Fellow of the American Academy of Cosmetic Dentistry, Dr. Berland maintains a premier cosmetic and family practice in Dallas. Widely published in professional and general publications, he lectures internationally and is the creator of a DVD/manual course (8 CE credits) on a two-appointment full-mouth rehab as well as the [www.denturewearers.com](http://www.denturewearers.com) Web site.

# Dentures

as full-mouth reconstruction

PART 1: THE FIRST TWO VISITS

By Dr. Lorin F. Berland


In 1996, the *Journal of Dental Research* estimated that about one-quarter of all 65-year-olds in America were completely edentulous; for those 75 years or older, that increased to 44%. And these individuals are often unnecessarily saddled with old, uncomfortable, and unattractive dentures. For many, time, expense, health issues, and personal preference rule out implants when it comes to

A great set of dentures can improve appearance and lifestyle. Here are some tips for ensuring the highest esthetics, function, and comfort.

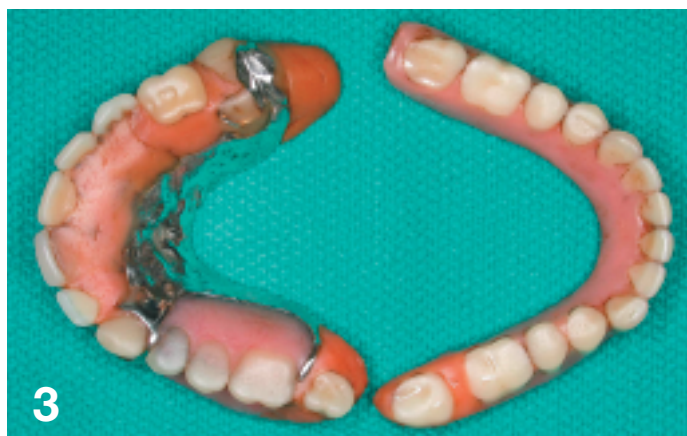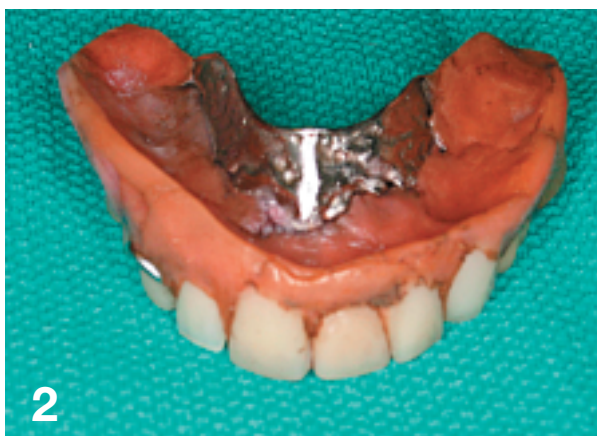rehabilitating their mouths.

How valuable are comfortable, attractive, functioning dentures? The answer is—invaluable.

Dentures are not just teeth. They can rejuvenate the face, recreate proper facial



## FIRST VISIT



(1) A full-face view of the patient wearing his existing dentures. (2) The patient has been wearing this maxillary denture for about 35 years. (3) The maxillary denture is shown with the mandibular denture, which is about 12 years old. (4) To help denture patients become educated consumers, a variety of detailed information is provided at [www.denturewearers.com](http://www.denturewearers.com).



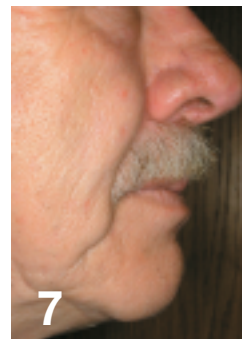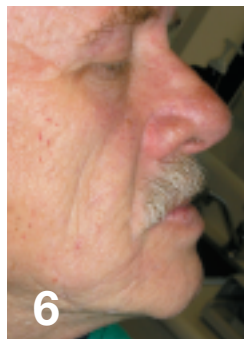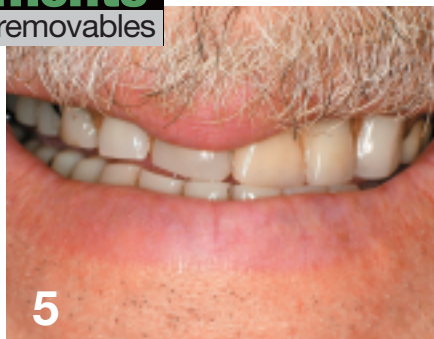proportions, and even reduce wrinkles. Dentures can make a person look and feel younger. They improve chewing and digestion and in turn, nutrition. They can affect the very quality of life. Dentures help with communication, from facial expressions to articulation. They can even protect the TMJ complex by acting as occlusal splints. Finally, for the right patient, new dentures can be cosmetic dentistry at its best.

### Our patient

The gentleman in **Fig. 1** began losing teeth in his late teens. Removable partial dentures were made. This began a pattern. As time went on, more teeth needed to be removed, beginning with the next abutments due to the strain of the clasps of the removable partial dentures. With each successive extraction, another tooth was added to the partial dentures. By the time he was in his late 20s, he had full upper and lower dentures made on the original partial frameworks. His current maxillary denture is approximately 35 years old, and the mandibular denture is about 12 years old (**Figs. 2 & 3**). The patient knew it was time for a change. A successful businessman, he easily could have afforded an implant solution. However, he correctly surmised that treatment would best start with the construction of new dentures. Surely, he thought, dentures must have improved in the last 30 years.

His Internet search for “new cosmetic  
*Continued on page 74*

(5) A close-up with dentures in place. (6) To simulate correction of collapsed occlusal vertical dimension, ... (7) ...the patient bites on cotton rolls, creating an attractive profile.



**White Towel**  
jr 1/2 h

See us at the XXX Meeting, Booth XXX.  
Use XXX on card or at [www.dentalproducts.net](http://www.dentalproducts.net)

**Miltex**  
jr 1/2 h

See us at the XXX Meeting, Booth XXX.  
Use XXX on card or at [www.dentalproducts.net](http://www.dentalproducts.net)

*Continued from page 72*

dentures” led him to my Web site, [www.denturewearers.com](http://www.denturewearers.com) (See Fig. 4). The site is intended to provide accurate information to help patients become educated consumers, and thus better denture patients.

Before his appointment, he filled out the patient health history online. In addition to customary questions, we wanted to know his denture history. The more we know about our patients, the better. Here are some questions we ask:

- Is it a full or partial denture? Top or bottom?
- When was the first denture made?
- How many different sets of dentures have you had?
- When was the last denture made?
- Is it uncomfortable?
- Is it loose?
- Does it slip?
- Is it difficult to eat certain foods?
- Is it difficult to talk?
- How does the denture look?
- Did the denture always have these problems?
- What is most important: appearance, comfort, fit, or function?

### Initial visit

At our initial consultation, we evaluate his existing dentures. We examine the denture base for cracks, breaks, discoloration, and odor, as well as over-extended and/or under-extended borders. The denture teeth also are examined. They may be worn, missing, broken, or all three.

The intraoral examination and panoramic radiograph help us evaluate ridge quality, salivary flow, and frenum and muscle attachment level. We also screen for oral cancer and incorporate digital photography to help better care for our patients. Typical views include, but are not limited to:

- a) Full face with (Fig. 1), and without dentures
- b) Close-up with (Fig. 5), and without dentures
- c) Maxillary arch and mandibular arch

### Extraoral evaluation

We evaluate the whole face. We pay particular attention to the facial dimensions, especially the lower third. We begin with the angles of the mouth, the lip support, the distance from the nose to the chin, the profile, the wrinkles, and the midline.

### Vertical dimension

Many long-time denture wearers have collapsed occlusal vertical dimension. A simple way to demonstrate how an increased vertical dimension may positively effect a patient's face and profile is to have the patient bite onto two cotton rolls, one on each side. The patient then can easily see the difference, as he immediately demonstrates an improved appearance. The lower jaw retracts from a pseudo Class III prognathism (Fig. 6) to a more attractive Class I orthognathic profile (Fig. 7). Our patient called this “facial augmentation.”

## Beginning treatment

Clinical examination revealed signs of abnormal tissue. All common symptoms of denture stomatitis were apparent: swelling, discoloration, hyperplasia, and bone loss.

In this case, wearing ill-fitting dentures for a long period of time and the resulting loss of vertical dimension were the main causes of these conditions. Over time, this resulted in excessive occlusal load on the anterior teeth. I advise such patients to leave their dentures out as much as possible for at least 7 to 14 days and to rinse frequently with warm salt water. However, most people are reluctant to

leave their dentures out, and our patient was no exception.

## Interim healing

I cannot expect my patients to go without their dentures. I use Hydro-Cast Tissue Treatment tissue-conditioning and functional impression material (Sultan Health-

care, [www.sultanhealthcare.com](http://www.sultanhealthcare.com)) whenever I replace full dentures. When left in the denture for 7 to 14 days as a liner, the material helps the healing process and improves denture retention and stability; it eliminates uneven pressures caused by an ill-fitting base and helps inflamed edentulous tissue return to normal health.

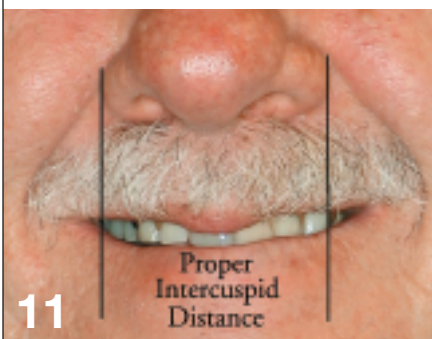
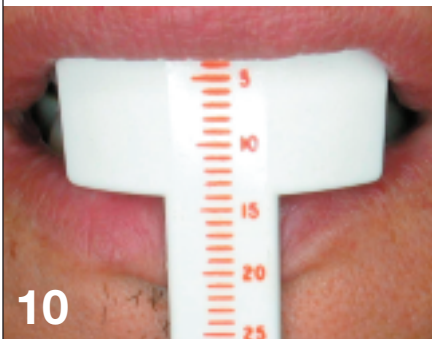
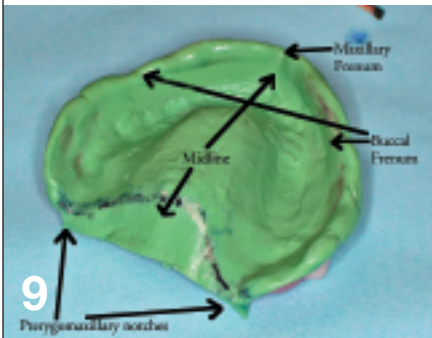
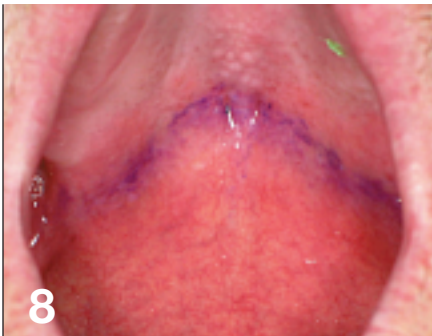
The liner makes the old denture feel better, painlessly and immediately.

## Initial impressions

New dentures begin with a good first impression. I use Accu-Dent System 1 alginate impression material (Ivoclar Vivadent,

*Continued on page 76*

## SECOND VISIT



(8) The vibrating line is marked...  
 (9) ...and transferred to the impression.  
 (10) The papillameter helps determine how much of the upper incisors should show. (11) The ala width is typically equal to the intercuspid width.

Orange County  
Standard Page

See us at the XXX Meeting, Booth XXX.

Use XXX on card or at [www.dentalproducts.net](http://www.dentalproducts.net)

For sales visit, circle XXX on card

*Continued from page 75*

*www.ivoclarvivadent.us*) because it has two viscosities—one for the tray and the other for the syringe. It also has several varieties of upper and lower tray sizes. The poured models were used to fabricate custom upper and lower trays for my patient's next appointment.

### Second visit

After two weeks of wearing his old dentures with the tissue conditioner, we were ready for the final impressions.

### Final impressions

I use Genie vinyl polysiloxane (Sultan Healthcare, *www.sultanhealthcare.com*), which comes in heavy, medium, and light viscosities, each of which is offered in both rapid (2:10 minutes) and standard (4:30 minute) set. I can use it in a Penta machine or in impression guns. I generally like to take final impressions with heavy body at the borders and light body in the tray and the mouth, standard set. With “gaggers,” however, I may choose medium body and rapid set.

### Post-dam transfer

After taking the maxillary impression, I have the patient hold his nose and blow. I mark the vibrating line with an indelible marker (**Fig. 8**). This is just beyond the junction of the hard and soft palates from the two pterygo-maxillary notches laterally to approximately 2 mm in front

of the fovea palatini at the midline. It is always on the soft palate. I then replace the impression in the mouth to transfer the marked junction to the impression (**Fig. 9**). This will help create a posterior palatal seal for a better, tighter maxillary denture.

### Biometric principles of teeth

Just like any cosmetic dental treatment, pleasing esthetics in the smile zone can make or break a denture case. There are certain tools and rules I use to help determine the length, depth, and width of the six maxillary anterior teeth. I take my first measurement with a papillameter (Aurum Group) (**Fig.10**). This helps determine how much of the upper incisors should show under the upper resting lip. The patient is asked to stand or sit upright. Holding the papillameter perpendicular to the floor, the incisive papilla rest is placed on the incisive papilla. The upper lip rests over the vestibular shield, making sure the upper lip is not being pushed up or outwards by the papillameter. With eyes level with the low lip-line of the upper lip at rest, I note the measurement on the papillameter. Then I have the patient smile and note the high lip measurement. This helps us to select the proper length of the anterior teeth for natural results.

The sum of the width of the maxillary anteriors, or the intercuspid distance, is generally equal to the space between the two nostrils. In other words, with certain variations like

*Continued on page 78*



(12) The *Smile Style Guide* helps patients choose incisal shape and relative length of the six upper anteriors.

**Addent**  
digest

**Rhein**  
digest

Continued from page 76

a wide or narrow nose, the ala width is generally equal to the intercuspid width (**Fig. 11**). This distance can be recorded and transferred to an impression of the old denture. The chosen maxillary anterior teeth can then be delivered, set, and verified at the next visit for records.

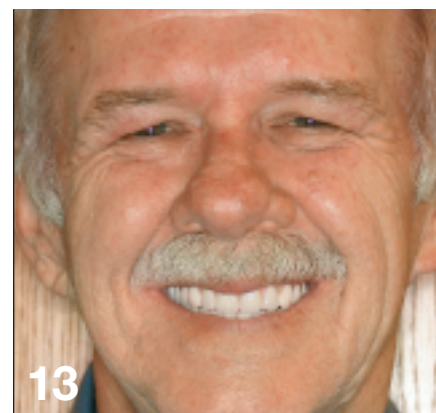
### Tooth selection

If the patient likes the appearance of the teeth in the existing denture, simply take an impression of the denture to match the teeth and then select a color. However, I find that is rarely the case. Once we have the length, width, color,

and depth of the 6 maxillary anteriors, it's necessary to choose the shape and relative length of the incisal edges. This is what gives a smile its individual personality. I use my *Smile Style Guide* (**Fig. 12**) ([www.digident.com](http://www.digident.com)) to help my patients see what they want. It is a great way to choose the proper incisal shape

## Brasseler

Standard Page



**(13)** Cosmetic imaging is used to help visualize the final outcome.

and relative length of the upper front teeth. First, we determine from a profile view what shape of the cuspid the patient finds most attractive: flat, pointed, or round. Then, we determine the shapes and combinations of the four maxillary incisors, square, square-round, and round that the patient likes. Lastly, we determine which relative length combination of the six upper front teeth appeals to the patient. Our patient chose P-2 pointed cuspids, square round laterals and square centrals, and L-1 even length.

I also use the *Smile Style Guide* for cosmetic imaging (**Fig. 13**). Cosmetic imaging can sometimes serve as the diagnosis, prognosis, treatment plan, and wax try-in—all before your ever touch the patient.

### Tooth shade

Shades have become more critical in today's appearance-conscious society. Most people want to look younger and desire to have whiter teeth. Denture wearers are no exception. This is full-mouth rehabilitation, so there are no existing teeth to match. I let the patient decide. When in doubt, go lighter. We chose A-1.

### Gingival shade

When it comes to their gums, most denture wearers prefer to match their natural color. Vident, Heraeus-Kulzer, Dentsply, and Ivoclar all make useful gingival shade guides.

The second appointment is now completed. The next appointment will involve taking a variety of clinical records such as vertical dimension and arch tracing. The try-in appointment follows and the final dentures are delivered at the fifth appointment. **DPR**

### References

1. Tassarotti B. A Clinical and Histological Evaluation of a Conditioning Material. *J Pros Dent* 1972;28:13-8.

**Part 2 of this case, detailing the final three visits, will be presented in the November issue of DPR.**